The BEAM

Winter 2016

Mississippi Society of Radiologic Technologists

Affiliated with the American Society of Radiologic Technologists

Contents

Letter from the President

MSRT Members:

I am deeply honored to have the opportunity to serve the Mississippi Society of Radiologic Technologists for my second term as President for the upcoming year. The support and encouragement from fellow colleagues has been incredible, and I look forward to working with a knowledgeable, hard-working MSRT Board of Directors again this year.

As president of the MSRT, I encourage all members to become involved in both your state professional society (MSRT) as well as the national society (ASRT). There are numerous ways you can become involved; the easiest of those is to become a member. Becoming an active member of the MSRT will provide you the opportunity to network with other individuals in your chosen profession. We are here to help guide you in your professional growth and development. Please don't hesitate to reach out to a member of the MSRT Board of Directors to find out how you can volunteer.

You are more than welcome to attend the January 2017 meeting of the Board of Directors. This will give you a chance to find out what opportunities for service are available. Volunteering for the MSRT is a great way to give back to your profession, while networking with others who share common interests. To find out more details, email msrt.biz@gmail.com.

Thank you, again, for your support! The MSRT is a strong affiliate society, and I am excited to serve in this leadership capacity for what will be another great year!

Sincerely,

Kristi Moore, PhD, RT (R) (CT)

MSRT President, Executive Secretary, & Website Administrator

Technologist of the Year!!

Sherrill Wilson

WOW! What a surprise and honor to be named MSRT Technologist of the Year for 2016. My heartfelt thanks to the selection committee for granting me this honor. I have been fortunate, over the years, to work with some great students and technologists on the MSRT Board of Directors in promoting our profession, and I will continue to do so as long as I am able. Thank you again for this great honor.

Sherrill Wilson, RT (R)

Mississippi Society of Radiologic Technologists

Affiliated with the American Society of Radiologic Technologists

The **MSRT Business Meeting** for the 75th Annual Conference was held at The Hotel Vue Conference Center in Natchez, MS, on October 25, 2016. Dr. Kristi Moore, President of the MSRT, welcomed those present and thanked everyone for attending Conference.

A quorum was established and the meeting was called to order by the MSRT President, Dr. Kristi Moore, at approximately 5:05 p.m.

The minutes from Conference 2015 were accepted as published in The BEAM.

The following reports were given:

1. **Treasurer:**
   A. Please refer to **Appendix A** for the MSRT Annual Financial Report that was presented at the business meeting.
2. **Vice-President:** Nothing to report.
3. **Secretary:** Nothing to report.
4. **Editor of The BEAM:**
   A. The deadline for the next issue of The BEAM is set for November 15, 2016.
      a. Please have all pictures to Leigh Moser prior to this date.
5. **Executive Secretary/Website Administrator:**
   A. As of October 25, 2016, there are a total of 359 MSRT members: (see **Appendix C**)
      a) Active Members (RTs)- 142
      b) Associate Members- 3
      c) Honorary Members- 2
      d) Life Members- 10
      e) Students- 202
6. **ASRT Affiliate Delegates:**
   A. Diane Mayo and John Melvin represented the MSRT as ASRT Affiliate Delegates at

the June 2016 ASRT House of Delegates Meeting in Las Vegas, NV.

a) The report can be found in the summer 2016 issue of The BEAM at www.msrt.biz.

7. Operating Budget:

A. John Melvin, Chairman of the Board, presented the proposed operating budget for 2016-2017 that was approved by the Board. (see **Appendix B**)

8. President:

A. Attended the June 2016 ASRT House of Delegates meeting in Las Vegas, NV. The meeting was great; however, not a lot was discussed. Encouraged everyone to stay involved and accept opportunities.

9. Conference Coordinator/Conference Chair:

A. There are currently 168 attendees preregistered:

a) Active Members (RTs)- 67 (including board members)

b) Student Members- 101

B. A loss is expected on the 75th Annual Conference. More information will be provided at the January Board of Directors Meeting.

Old Business: None.

New Business: None.

10. Nominations:

A. Nominations for officers included:

a) President- Dr. Kristi Moore

b) Vice President- Lee Brown and Robbie Nettles

c) Secretary- Mandy Pearson

d) ASRT Affiliate Delegate- Shazowee Edgerton, Leigh Moser, and Sherrill Wilson

1) Election held for Vice President and ASRT Affiliate Delegate

i. Lee Brown elected as Vice President

ii. Leigh Moser elected as ASRT Affiliate Delegate

With no further business to be discussed, the meeting adjourned at approximately 5:33 p.m.

Respectfully submitted,

Mandy Pearson, MS, RT(R)

Mandy Pearson, M.S., R. T. (R)

Appendix A

Annual Report to the Board

October 25, 2016

Checking Account as of October 21, 2016 $45,585.14*

*Includes Student Account of $3,359.30

Investment Account as of September 30, 2016 -- $66,656.10

CD #3908 as of 7-27-16--$11,966.79(Next payment date Oct.27, 2016)

CD #2333 as of July 28, 2016--$21,298.26 (Next payment date Oct. 28, 2016)

CD #1055 as of Nov. 15, 2015--$35,075.17 (Next payment date Dec. 12, 2016)

CD #3208 as of August 06, 2016--$15,445.42 (Next payment date Nov. 6, 2016)

Total Assets **$196,026.88**

As of this date, only a deposit of $1500.00 has been paid toward conference.

Respectfully Submitted

Paula Young, BS RT (R)(M)

MSRT Treasurer

MISSISSIPPI SOCIETY OF RADIOLOGIC TECHNOLOGISTS

PROPOSED OPERATING BUDGET 2016-2017

President- 500.00

Vice-President-25.00

Chairman of the Board-100.00

Alternate ASRT Delegate-2000.00

Secretary-25.00

Treasurer (Salary)-599.00 (Budget)-100.00

Executive Secretary (Salary)-599.00 (Budget)-200.00

The Beam-1000.00

Conference Coordinator-2000.00

ASRT Affiliate Delegate x2-500.00 each

Manuscript Participation-600.00

R.T. Exhibits-200.00, 150.00 and 100.00

Student Exhibits-200.00, 150.00 and 100.00

R.T. Manuscripts-200.00, 150.00 and 100.00

Student Manuscripts-200.00, 150.00 and 100.00

Student Scholarships-2000.00

Fax Capabilities for OJT Coordinator-480.00

Accountant-2000.00

Pay Pal Fees-700.00

Internet (Wild Apricot/Bank Fees)-600.00

Total: 16,328.00

Executive Secretary/Website Administrator's Report

October 25, 2016

The following is a list of MSRT membership as of October 25, 2016:

- Active Members (RT's) – 142
- Associate Members – 3
- Honorary Members – 2
- Life Members – 10
- Student Members – 202
- **Total Members – 359**

MSRT Conference 2016 Speakers

Patricia Brewer

Catherine Cooper

Cherie Pohlmann



Roy Haynes

Susan Reyes

Richard "Fuge" Fucillo

Deborah Shell

MSRT Conference 2016 Speakers

Melissa Jackowski
ASRT Vice President

Travis Prowant
ARRT Board Trustee

Thank you!

Student Papers were mailed to three (3) out-of-state judges for the student manuscript competition. Pictured below are the six students whose papers were selected for manuscript competition.

- **"Forensic Radiology" by Elizabeth McPheters**

  Received 1st Place

- **"Caffey Disease" by Camille Bankston**

  Received 2nd Place

- **"Shine Bright Like a Diamond: Magnetic Modulation of Fluorescent Nanodiamond Emission" by Lexus Watson**

  Received 3rd Place

- **"X-Rays in the Morgue" by Sara Beth Grant**
- **"Hutchinson- Glifford Progeria Syndrome" by Jennie Meredith**
- **"Computed Tomography on Cadavers" by Audrey Wilson**

Left to Right - Audrey Wilson, Sara Beth Grant, Camille Bankston, Elizabeth McPheters, Lexus Watson, Jennie Meredith

Student Manuscript: 1st Place Recipient - Elizabeth McPheters (UMMC)

Forensic Radiology

Forensic radiology has been in use since x-rays were discovered. Professionals knew from the beginning that this branch of radiology would be very valuable in assisting police, coroners, lawyers, and other personnel in closing cases. Over the past 120 years, forensic radiology has progressed leaps and bounds. Not only do we use basic radiography, but now computed tomography (CT) and, sometimes, magnetic resonance imaging (MRI) are in effect, too. A few ways radiology is used is by confirming the identity of victims, obtaining the cause of death, unearthing the perpetrator, etc. (Brogdon, 1998).

On November 8, 1895, Dr. Wilhelm Conrad Roentgen discovered x-rays. Later that month, he produced the first ever radiograph using his wife, Bertha's, hand. The first time x-rays were taken because of a crime was in December of that same year. Mr. Tolson Cunning was shot in the leg by Mr. George Holder. The bullet that was lodged in Mr. Cunning's leg was originally unable to be removed, eventually healed over, but still showed infection. John Cox, a physics professor, was asked to x-ray Mr. Cunning's lower leg. After a 45 minute exposure, the bullet was found to be lodged in between the victim's tibia and fibula. The radiograph was used in court, and Mr. Holder was convicted and sentenced to 14 years in jail. The first murder case where forensic radiology was put to use occurred on April 23, 1896, when Elizabeth Ann Hartley was shot in the head by her husband, Hargreaves Hartley. Mr. Hartley immediately committed suicide after the incident. Miraculously, she survived the next 16 days. During those couple of weeks, her doctor, Dr. William Little, requested Arthur Schuster to help him locate the bullets in Mrs. Hartley's skull. Arthur Schuster was a physics professor who followed Roentgen's work in x-rays. Schuster was sick at the time, so he sent his assistants, C. Lees and A. Stanton. The first two exposures they took lasted 60 and 70 minutes. These revealed three bullets.

bullets. Professor Schuster was able to make it to Mrs. Hartley on May 2nd. He took a third exposure and found the last of the four bullets. Sadly, all bullets were unable to be removed and Elizabeth Hartley died on May 9, 1896. These two cases, and several others soon afterwards, became the forefront of forensic radiology (Brogdon, 1998).

Forensic radiology now uses several different types of modalities. The main two are CT and digital radiography; however, MRI is also slowly becoming more common in the forensic world. Each one contributes in its own, unique way. Of course digital radiography will always be of use, but CT and MRI are gaining notoriety for their ability to reconstruct bodies and body parts three dimensionally. They are often used in what is called a virtual autopsy that professionals would perform before an actual autopsy (Kudlas, Odle, & Kisner, 2010). According to Dr. Giuseppe Guglielmi, "If you are looking for specific details in the skin, you can make a reconstruction of the skin; if your investigation centers on the skeleton, you can reconstruct bones; and if you are looking at organs, you can reconstruct the soft tissue. You can manipulate the images to find the exact answer you are looking for" (as cited in Lee, 2013, para. 5).

Multidetector computed tomography (MDCT) is also helpful in finding entry and exit points of bullets and other foreign matter. A downside to this, compared to a living person, is that there is an inability to use contrast. Contrast would allow the viewer to differentiate between tissues. MRI, alone, is often used to see the nervous system (Kudlas, et al., 2010). Yet, at this point, MRI is used in few cases because it is harder to apply to a postmortem body than a living one (Lee, 2013). These modalities have been helpful when used as a replacement for traditional autopsies, especially in cases where the body could not be opened due to religious reasons. Although some people still believe that CT and MRI scans alone are not enough to stand trial, they are becoming more widely accepted (Kudlas, et al., 2010).

"The use of forensic radiology can provide the victim's age, sex, stature and other information" (Kudlas, et al., 2010, p. 11). This allows us to identify a body as a specific person. Every individual's body is built differently and has had different situations in life that may cause further uniqueness. For example, one person may have had a specific fracture in their left tibia when they were 15 years old. If that same person died with no positive source of identification, professionals would be able to pull x-rays images from the suspected identity and compare the clinical image to the forensic one (Kudlas, et al., 2010). "Computerized record keeping, available in most hospitals, expedites the retrieval of individual x-ray films, making radiographic comparison one of the most common techniques used by forensic radiologists in order to establish a positive identification of unknown remains" (Kahana & Hiss, 1997, para. 4).

One of the most common uses of radiography to identify a person is through dental profiling. It is especially important in cases where the victim is fairly unrecognizable. An example would be a burned corpse; or one so decomposed that only the skeleton is left to use for identification. Images of a victim's teeth can be taken, and from them the age, sex, and even ethnic group can be recovered. One way to figure out the age of a victim from an image is the size of the dental pulp cavity. As a person ages, their pulp cavity becomes smaller. Just like professionals will compare clinical radiographs to postmortem radiographs to discover the identity of a corpse, they will also compare dental records of the suspected identity to the images of the victim. Some factors that are compared are the number and arrangement of teeth, cavities and repairs, bony landmarks, frontal sinuses, maxillary sinuses and nasal apertures, pathologies, etc (Manigandan, Sumathy, Elumalai, Sathasivasubramanian, & Kannan, 2014). Dental profiling is also very helpful in identifying the victims of mass casualties such as floods, fires, bombings, and other unfortunate circumstances. The use of CT in dental profiling is newer but very helpful. A proceedure called a Dentascan is used. A panoramic view of the jaws, teeth, anatomic

structures of the bone, pathologies, and restorations is created. The biggest benefit, like the CT 3D reconstruction of the body, is the fact that it is non evasive (Manigandan, et al., 2014).

Another way forensic radiology plays an important role in crime investigations is the determination of the cause of death. A couple possible causes of death are blunt force trauma and gunshot wounds. Blunt force trauma is defined as "injuries resulting from an impact with a dull, firm surface or object" (Batalis, 2016). MDCT is probably the most useful method in determining this type of trauma. In a closed head trauma, cerebral contusions will appear as linear areas with high attenuation, and next to these cerebral contusions, a low attenuation of fluid is normally found. Hematomas on the brain also appear as areas with high attenuation. MDCT, along with general radiographs can easily find fractures and displacements from blunt force trauma. "Fractures are linear, angulated, or displaced lucencies within bone" (Levy, 2012, para. 9). Compression fractures are marked as areas with lower body height or lower attenuation because of the compression. Gun shot wounds are very easily seen through radiography. Areas where a victim has been shot are linear, darker because of gases, and contain whole bullets or fragments. These areas may also contain bone fragments if the bullet passed through (Levy, 2012). Through the radiographic images taken of a gunshot victim, the identification of wound tracks and localization of the projectile can be found. "The directionality of fragments and beveling of bone toward the direction of travel may establish bullet path and help differentiate entry versus exit wound" (Weerakkody & Stanislavsky, 2016,). The location of a bullet can be found based off of the track it has made through the body. If a bullet is not found within the body, and exit wound is then searched for (Weerakkody & Stanislavsky, 2016). When blunt force trauma and/or bullet wounds are found on a victim, radiographs and CT help investigative professionals find which specific objects caused these injuries. This also, in turn, helps these professionals find the criminal associated with these weapons.

Forensic radiology has contributed so much to the world of crime and investigation. As soon as radiographs were discovered, professionals began applying them to investigations. Now, we are also using computed tomography (CT) and magnetic resonance imaging (MRI), along with radiographic images. Without it, identification of some bodies would take much longer to obtain, if at all. Professionals can also determine the cause of death through these images. The use of forensic radiology is a great alternative or addition to traditional autopsies. It allows professionals to get an internal view of the body without invasive procedures. H. Z. Mellins, M.D., once said, "The radiologist perceives a shadow, sees a lesion, and imagines a man. The bedside physician sees the man, perceives the signs and images the lesion. They practice from the outside in and we from the inside out" (as cited in Brogdon, 1998, p. 4).

References

Batalis, N. (2016). *Forensic autopsy of blunt force trauma.* Retrieved from http:// emedicine.medscape.com/article/1680107-overview

Brogdon, B. G. (1998). *Forensic radiology.* New York, NY: CRC Press.

Kahana, T., & Hiss, J. (1997). Identification of human remains: forensic radiology. *Journal of Clinical Forensic Medicine, 4,* 7-15. doi:10.1016/S1353-1131(97)90002-X

Kudlas, M., Odle, T., & Kisner, L. (2010). *The State of Forensic Radiography in the United States.* Retrieved from https://www.asrt.org/docs/default-source/whitepapers/forensic_ radiography_white_ paperfin.pdf?sfvrsn=2

Lee, S. (2013). *Advances in forensic imaging bring new opportunities for radiology.* Retrieved from http://www.auntminnie.com/ index.aspx?sec=rca&sub= ecr_2013 &pag=dis& ite mId=102753

Levy, A. (2012). *Postmortem radiology and imaging.* Retrieved from http://emedicine.medscape.com/ article/1785023-overview#a3

Manigandan, T., Sumathy, C., Elumalai, M., Sathasivasubramanian, S., & Kannan, A. (2015). Forensic radiology in dentistry. *Journal of Pharmacy & Bioallied Sciences, 7*(Suppl 1), S260–S264. doi: 10.4103/0975-7406.155944

Weerakkody, Y., & Stanislavsky, A. (2016). *Imaging of gun shot injuries.* Retrieved from http:// radiopaedia.org/articles/imaging-of-gun-shot-injuries

Radiologic technologists have the opportunity to participate in the RT category of both scientific manuscript and exhibit competitions at the MSRT Conference each year. Technologist papers were mailed to three (3) out-of-state judges for the radiologic technologist manuscript competition. Pictured below are the five technologists whose papers were selected for manuscript competition.

- "Medical Imaging for Coronary Artery Disease"
  by Tyler Gray, B.S., R.T.(R)
  Received 1st Place
- "Multiple Sclerosis" by Anne Howard Steinwinder, B.S., R.T.(R)
  Received 2nd Place
- "Meningioma" by Savannah Gillis, B.S., R.T.(R)
  Received 3rd Place
- "Parkinson's Disease" by Kala Ford, B.S., R.T.(R)
- "Pediatric Strokes" by Alexa McGuire, B.S., R.T.(R)

Left to Right - Anne Howard Steinwinder, Savannah Gillis, Tyler Gray, Kala Ford, Alexa McGuire

Technologist Manuscript: 1st Place Recipient - Tyler Gray B.S., R.T.(R)

"Medical Imaging for Coronary Artery Disease"

Heart disease is the most common cause of death in the United States. Coronary artery disease (CAD) is the most common form of heart disease and is responsible for 370,000 deaths annually. There is no cure for CAD, but early diagnoses and treatment can help slow the progression of the disease. Medical imaging has been used extensively for over the past 40 years as the leading way to diagnose CAD. Multiple imaging modalities, including sonography and nuclear medicine technology can serve a purpose in diagnosing heart disease. However, conventional angiograms, computed tomography (CT), and magnetic resonance imaging (MRI) are at the forefront for the diagnoses of CAD. While these three modalities are frequently used to examine the same anatomical structures of the heart, the method and procedure of acquiring the images are very different.

Conventional angiograms and CT are the most effective means of acquiring images of the coronary vessels, however, the use of radiation and iodinated contrast injections to produce images leads to potentially harmful effects for the patient. The use of radiation and iodinated contrast is not required for MRI. MRI uses a strong magnetic field and special coils to receive high frequency signals to produce detailed images of the heart and coronary vessels, however, MRI has its disadvantages. In MRI, cardiac motion and length of scan time can lead to an undiagnostic study. All three modalities have their strengths and flaws (Agunwamba, Argenio, Fareed, Hanson, M. A., Hanson, T. R., 2013).

Coronary artery disease is a complex disease in which a substance termed “plaque” sticks and builds on the walls of the coronary vessels. The coronary arteries are an intricate system of

vessels that encircle and feed oxygen to the heart. Accumulation of plaque causes reduced or absent blood flow in one or more of the coronary arteries. The heart is identical to every other muscle in the body, it needs a steady supply of oxygen to perform properly. The heart beats nearly 100,000 times per day. It is a hard working muscle and needs a lot of oxygen to function adequately. Visualize the last time you went out on a run. What did you feel during and after the run? You were probably gasping for air. The reason being, your muscles are using oxygen at a rapid rate. The body is trying to replenish those muscles with oxygen so they will continue working properly. Since the heart is a continually working muscle it to needs a significant amount of oxygen to keep functioning properly. This is the job of the coronary arteries. The coronary arteries branch directly off the ascending aorta. These arteries feed directly into the heart muscle or myocardium and keep the heart adequately supplied with oxygen rich blood (Lillyard & Theroux, 2005).

In coronary artery disease, the coronary vessel becomes obstructed and cannot adequately supply the heart with the oxygen it needs to function. This diseases commonly progresses and worsens over time. It is most prevalent in individuals with a history of high blood pressure, high cholesterol, and people who smoke. Poor diet and inadequate physical activity are also contributors to coronary artery disease. It is important to recognize potential warning signs of coronary artery disease. Angina is a common symptom of coronary artery disease. Angina is chest pain or discomfort that occurs because of inadequate blood supply to parts of the myocardium. Individuals with angina often think they are experiencing indigestion or gas. It is important for people with frequent angina, especially after exercise, to seek medical attention. If coronary artery disease is expected to be the etiology of the pain and discomfort, an appointment

with a cardiologist should be made (Agunwamba, Argenio, Fareed, Hanson, M. A., Hanson, T. R., 2013).

Several test can help with the diagnoses of coronary artery disease. Electrocardiogram, echocardiogram, and a stress test will be performed first. Electrocardiogram records the electrical signals as they travel throughout the heart. An electrocardiogram can reveal if the heart is beating out of rhythm. Certain abnormal signals can indicate insufficient blood flow to certain areas of the heart. An echocardiogram uses modified sound waves to see the heart beating in real time. With these images the cardiologist can determine if all parts of the heart are contributing to the normal pumping activity of the heart. If abnormal heart rhythms or and angina like symptoms occur primary during exercise, a stress test will be performed. A stress test is acquired by hooking up the individual to an electrocardiogram while walking on a treadmill. A stress with the inclusion of a nuclear medicine scan can show if the heart is receiving adequate blood flow during increased cardiac output. If the results of this test show the individual could have decreased blood flow due to coronary artery disease, more extensive testing may be performed (Mankad, 2015).

A coronary angiogram has been used extensively since the early 1960s to diagnose CAD. It has been the primary means of examining the coronary atrial system effectively. This procedure is also frequently termed heart catheterization. The test is conducted in a special room called a “cath lab.” The procedure is invasive, it requires the insertion of a small flexible catheter into the femoral, brachial, or carotid artery. The catheter is guided and placed into the coronary arteries. Once the catheter is in coronary artery, the cardiologist will inject an iodinated

contrast agent to make the vessel opaque. While the contrast agent or “dye” is injected images are taken using fluoroscopy. The images reveal the areas of blockage or stenosis of the coronary vessels. Although this method of detection is extremely accurate, it comes with risk. Conventional coronary angiography uses iodinated contrast, which could cause a serious anaphylactic reaction or induce renal failure. The insertion of the catheter can induce vessel spasm and/or a tear in the lining of the vessel. The procedure could also produce an embolism, which could travel to the brain and cause a stroke to occur. Coronary angiograms are extremely accurate but the use of a catheter, radiation and iodinated contrast agent make the exam a potentially harmful procedure (Bluemke et al., 2008).

Over the past decade, considerable advances have been made in noninvasive cardiac imaging. Computed tomography angiography (CTA) is one of those substantial advancements. Multi-detector CT (MDCT) uses x-rays with up to 256 detectors to acquire its images. MDCT can provide visually compelling images of the coronary arterial tree. It does this by spinning the x-ray tube and detectors in a 360 degree circular motion. X-rays attenuate as they are administered into the body. The attenuation of the x-ray beam is absorbed by the detectors. The signal absorbed by the detectors is then transmitted to a computer and transformed into a three-dimensional (3D) image. This method of visualizing the coronary arteries has proven to be extremely effective and reliable. However, the use of high doses of radiation and iodinated contrast is required to receive the images. Coronary CTA requires a rapid injection of intravenous administration of an iodinated contrast agent. Power injectors administer up to 160ml of contrast medium at a rate of 4 to 5ml per second. The injection is given through an intravenous catheter (typically 18 gauge or greater) and is preferably placed in

the right antecubital vein in the bend of the elbow. After the injection, the CT scanner searches for peak enhancement of the aortic root. Once peak enhancement is achieved, the machine begins to scan allowing for optimal enhancement of the arteries of the heart. If the individual has a blockage in the coronary artery, the area of blockage will not be enhanced. It will appear as a dark streak in the vessel. If the artery is completely blocked, the vessel will fill to the point of blockage and will not be able to progress any further (Bluemke et al., 2008).

CTA is sensitive to heart motion. The involuntary heart rate must be keep at a rate under 70 beats per minute (bpm) or a motion artifact will occur. The CTA cardiac motion artifact can obscure the coronary arteries and make the exam undiagnostic. To help control cardiac motion a lopressor or beta blocker may be given to ensure the heart rate stays below 70 bpm. The CTA procedure of diagnosing coronary artery disease is accurate and is noninvasive compared to a conventional coronary angiogram. However, the risk of allergic reaction, renal failure and the high doses of radiation exposure still pose potentially life threating risks for the patient (Bluemke et al., 2008).

Magnetic resonance imaging (MRI) has potential to become the new standard for the diagnoses of coronary artery disease (CAD). MRI uses a powerful magnetic field and sequences of pulse waves to produce signals. The signals are retrieved by specialized coils and transmitted into a computer program which converts the signals into detailed 3D images. Only in the past decade, has magnetic resonance angiography (MRA) become a viable way to view the vessels of the heart. The introduction of the 3 tesla magnet, high-speed gradient techniques and cardiac specialized coils have led to an increased visualization of the cardiac vessels in MRA (Bluemke et al., 2008).

Unlike coronary angiography and CTA, MRA is able to acquire images of the coronary vessels without the use of radiation and iodinated contrast agents. For individuals allergic to iodine and those in renal failure, this gives an accurate way to receive a diagnoses of CAD with the risks. While MRI is safer than conventional angiography and CTA, it has disadvantages. While performing an MRA of the heart, cardiac and respiratory motion must be accounted for. Motion can cause a blurring artifact of the coronary artery lumen unless adequate motion-suppression methods are applied. The best solution for controlling cardiac motion is to time the beats using an electrocardiogram and record signal during mid-diastole relaxation during the scan. Respiratory motion is controlled using breath-holding techniques. Navigator echoes can also help limit respiratory motion. "Navigator echoes track a patient's diaphragmatic motion. These images are attained while the diaphragm is within 3 to 5 mm of its end-expiratory position" (Bluemke et al., 2008).

In conclusion, CAD is a very serious condition affecting the lives of many people. The accurate diagnoses of CAD is critical in providing expedited treatment for the patient. Conventional angiograms, CTA and MRA are all beneficial in diagnosing CAD. Overall, MRI provides a safer way to diagnose CAD without the associated risks of conventional angiography or CTA. With future advancements to gradients and improved cardiac coils to reduce heart motion artifacts, MRA demonstrates the potential to replace conventional angiography and CTA in the diagnoses of CAD.

References

Bluemke, D. A., Achenbach, S., Budoff, M., Gerber, T. C., Gersh, B., Hillis, D., … Woodard, P. K. (2008). “Noninvasive Coronary Artery Imaging.” *Circulation* 118 (5). http://dx.doi.org/10.1161/CIRCULATIONAHA.108.189695

Lillyard, P., & Theroux, P. (2005). “Pathophysiology of Coronary Artery Disease” *Circulation* 111 (25). http://dx.doi.org/10.1161/CIRCULATIONAHA.105.537878

Agunwamba, A. O., Argenio, S. L., Fareed, M. T., Hanson, M. A., Hanson, T. R. (2013). “Coronary Artery Disease” *Primary Care: Clinics in Office Practice* 40, 1-16. http://dx.doi.org/10.1016/j.pop.2012.12.001

Mankad, R. (December 11, 2015) *Coronary Artery Disease*. Retrieved from http://www.mayoclinic.org/diseases-conditions/arthritis/expert-answers/arthritis-pain-medications/faq-20058391

Student Exhibits



"Fetal MRI"

1st Place & People's Choice

Students: Kasea Nations & Isabelle Ebbers

(Co-Lin Community College)

Student Exhibits

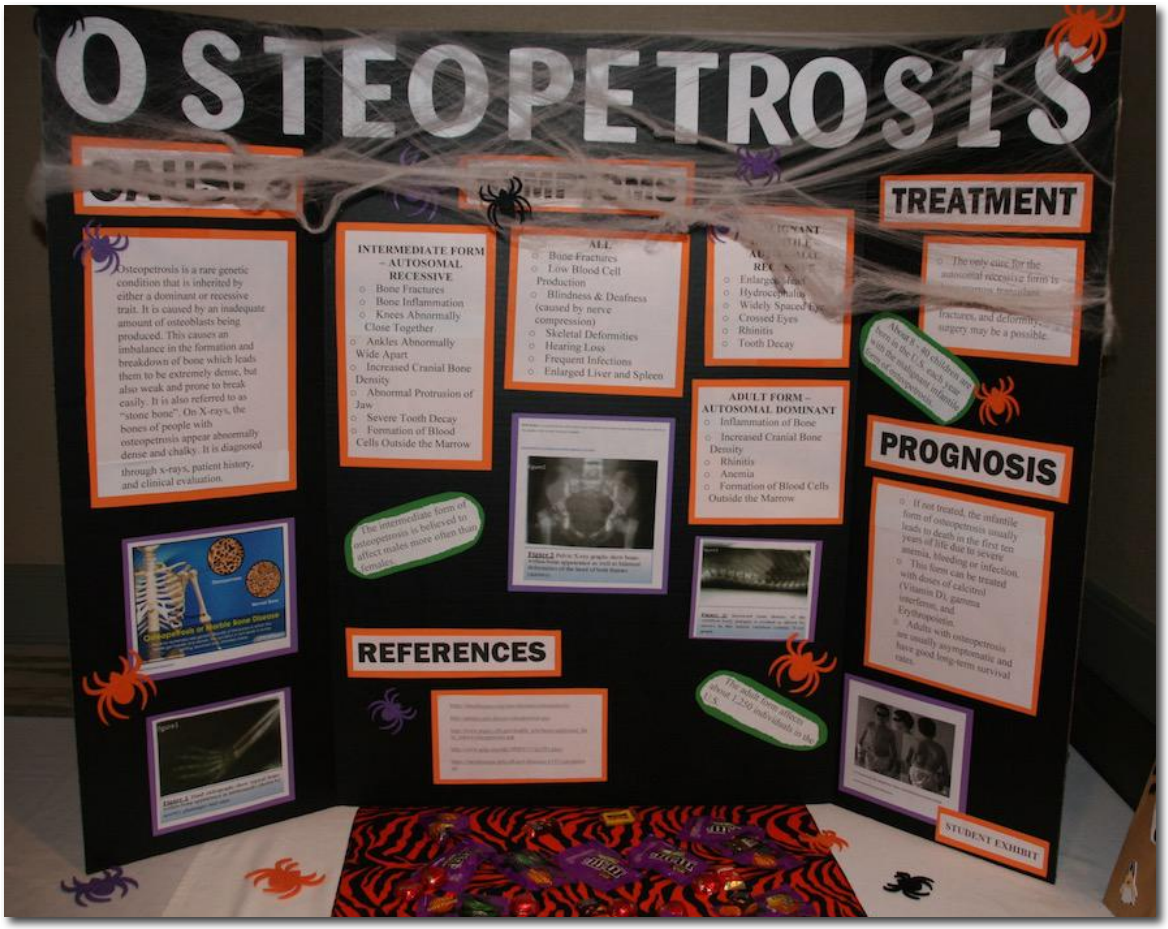

"Osteopetrosis"

2nd Place

Students: Sara Mayor & Julia Hotaling

(UMMC)

Student Exhibits



"Scoliosis: Bent but Not Broken "

3rd Place

Students: Brittany Walters & Toni Leverette (UMMC)

Student Exhibits



"Synovial Joints"

Students: (Hayden Sistrunk, Morgan Davis, & Emily Baughman)

(UMMC)

Student Exhibits

"Marble Bone Disease"

Students: Hannah Anderson & Kathleen Lott

(UMMC)

Student Exhibits



"Not Just for Humans"

Students: Kaitlyn Blanton, Lacey Sanford, & Morgan Lambert

(UMMC)

Student Exhibits



"Electric Slide"

Students: Zack Gray & Gunnar Boleen

(UMMC)

Technologist Exhibit



"Pediatric Strokes"

1st Place

Technologists: Kala Ford, B.S., R.T.(R); Tyler Gray, B.S., R.T.(R); Savannah Gillis, B.S., R.T.(R); Alexa McGuire, B.S., R.T.(R); Anne Howard Steinwinder, B.S., R.T.(R)

Technologist Exhibit

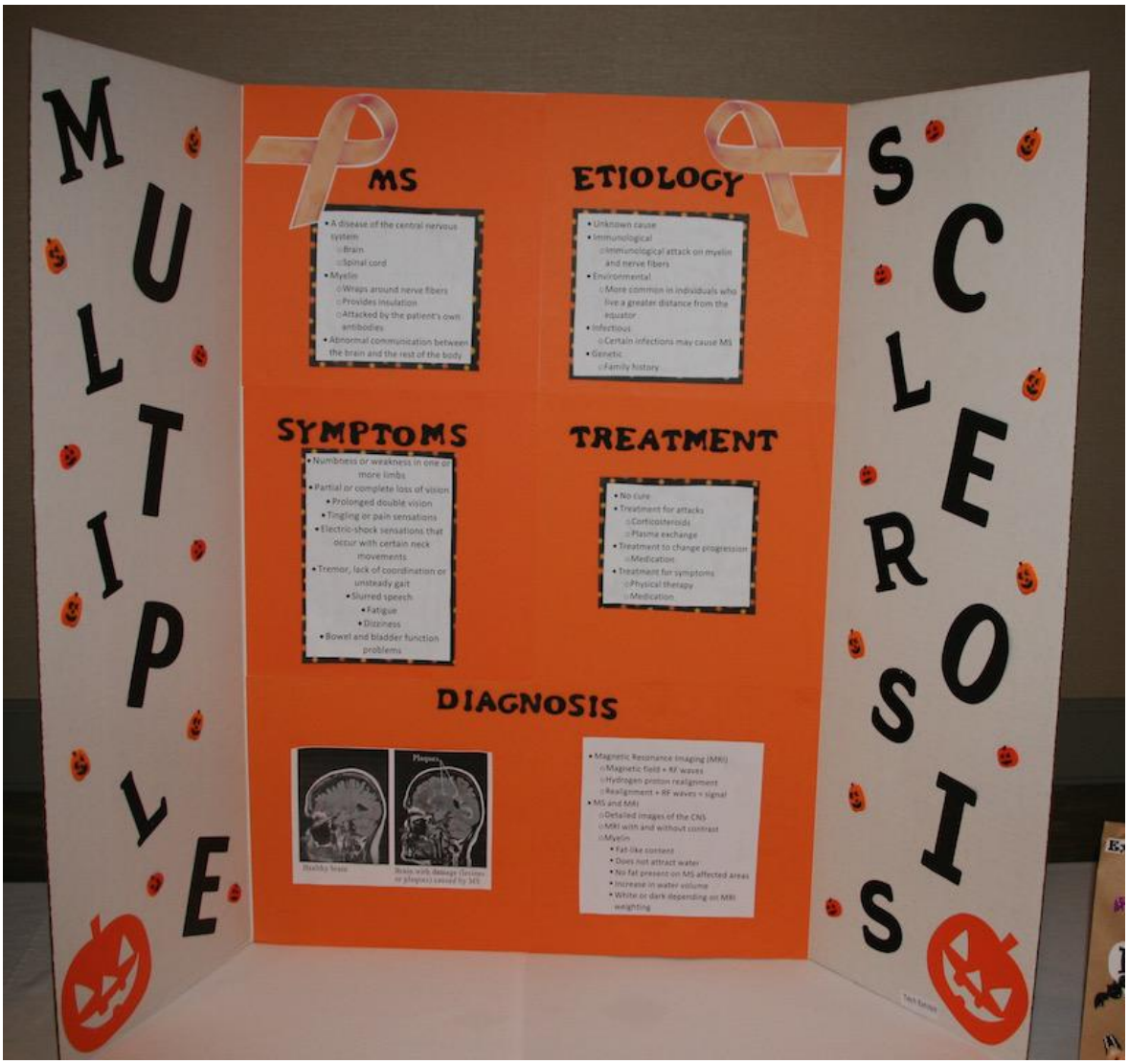

"Multiple Sclerosis"

2nd Place

Technologists: Kala Ford, B.S., R.T.(R); Tyler Gray, B.S., R.T.(R); Savannah Gillis, B.S., R.T.(R); Alexa McGuire, B.S., R.T.(R); Anne Howard Steinwinder, B.S., R.T.(R)

Technologist Exhibit

"MRI Safety"

3rd Place

Technologists: Kala Ford, B.S., R.T.(R); Tyler Gray, B.S., R.T.(R); Savannah Gillis, B.S., R.T.(R); Alexa McGuire, B.S., R.T.(R); Anne Howard Steinwinder, B.S., R.T.(R)

Congratulations!!

1st Place Technologist Exhibit

"Pediatric Strokes"

(L-R) Kristi Moore - MSRT President, Anne Howard Steinwinder, Alexa McGuire, Tyler Gray, Savannah Gillis, Kala Ford

1st Place Student Exhibit & People's Choice

"Fetal MRI"

(L-R) Isabella Ebbers, Kristi Moore - MSRT President, Kasea Nations

(Left) MSRT Elected Officers: (L-R) Mandy Pearson, Secretary; Lee Brown, Vice President; Kristi Moore, President; Dr. Melissa Jackowski, ASRT Vice President

(Below) Past President's Plaque presented to Kristi Moore by John Melvin

Congratulations!!

(Above) John Melvin & Leigh Moser - ASRT Affiliate Delegates

(Right) Student Delegates (L-R)- Summer Hutchinson (Jones County JC), Christian Chirinos (UMMC), Will Lindsey (UMMC, past delegate), Lexus Watson (Jones County JC, past delegate)

MSRT Scholarship Recipients

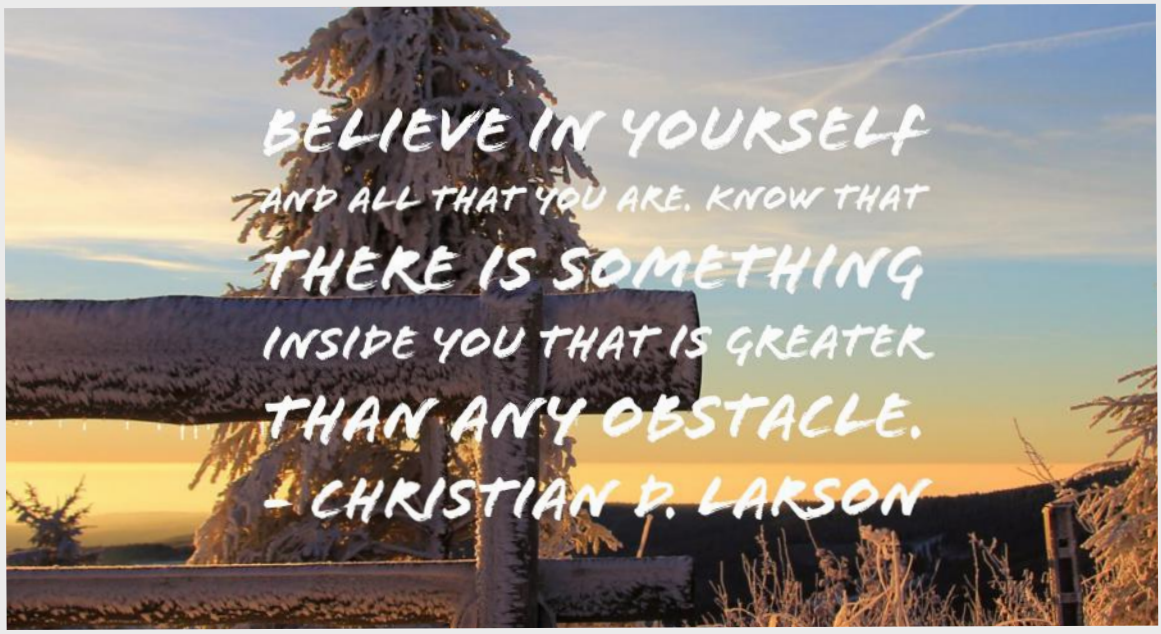

Each of these students has demonstrated outstanding academic and clinical performance throughout their education. We salute them and wish them well in their future endeavors.

MSRT Board of Directors

Congratulations!!

Kasea Nations

Co-Lin Community College

Emily Short

Itawamba Community College

KC Singley

Jones County Junior College



Lacey Hedrick

Meridian Community College

Valerie Headd

MS Delta Community College

Student Prep Bowl Competition

1st Place - Jones County Community College

(L-R) Brittany Welsh, Amanda Rowley, Grace (Ali) Carter, Katherine (KC) Singley, Lexus Washington

Student Prep Bowl Competition

2nd Place - Itawamba Community College

Front (L-R) Ben White, Lacey Wood, Mallory Conwill

Back (L-R) Hannah Stockton & Ashlynn Beam

Student Prep Bowl Competition

3rd Place - University of Mississipi Medical Center

Front (L-R) Jennie Meredith, Sarah Beth Grant, Audrey Wilson

Back (L-R) Zack Gray & Janie Turner

Student Prep Bowl Competition

Prep Bowl Participants - Copiah-Lincoln Community College

Front (L-R) Monica Ham, Kasea Nations, Annie Ross

Back (L-R) Taylor Nelson & Elizabeth Floyd

Student Prep Bowl Competition

Prep Bowl Participants - Mississippi Delta Community College

Front (L-R) Valerie Headd, Mary Thennissen, River Wolfe

Back (L-R) Lane DuBois & Peyton Clanton

Out and About


VENDOR

The Anniversary Dinner and Toast to 75 years!

MSRT

Costume Party





Letter from the Editor

Ya'll, this years conference was even better than last! I would like to take this opportunity to thank everyone involved for pulling off another great annual meeting. There is so much that goes on behind the scenes from planning and arranging schedules, to setting up the audio visual equipment. I challenge each of you to volunteer to be on a committee either for conference planning or on the MSRT board. We need to come together as a united front to make sure our profession thrives. Keep in mind our board meetings are open and anyone is invited to come. Our next meeting is scheduled for January 14, 2017 at noon. It will be held at the SHRP building on the UMMC campus. Remember to like our Facebook page, "MSRT- Mississippi Society of Radiologic Technologists". Announcements about future events and meetings will be posted on the page. Get connected!! I can't wait to see everyone October 2017 in Biloxi, MS!!

- Leigh Moser, R.T.(R)